



play intracellular functions in surface epithelial cells and in the underlying fibroblasts, while TGase3 is expressed in the upper epidermal layers and is localized in the cytoplasm. TGase3 is a well-known autoantigen in dermatitis herpetiformis, a blistering disease characterized by granular IgA deposits in the papillary dermis. These findings suggest that TGase3 may be the autoantigen involved in producing the skin phenotype. Furthermore, S100B has been described to be a potential biomarker for melanocyte cytotoxicity.

We hypothesize that these crossreactions between SARS-CoV-2 spike protein antibody and tissue proteins such as TGase2, TGase3, collagen and S100B may play a role in developing these immune-mediated skin disorders. As the mechanisms are still unclear, we have to consider that sensitization may occur over time, meaning that a reaction consistent with a BDR may occur rapidly upon renewed use of the drug. Finally, we stress the importance of reporting adverse skin reactions related to these new mRNA vaccines by healthcare professionals in order to promote pharmacovigilance systems and vaccine safety.

## Acknowledgement

We thank Dr B. Vivanco-Allende of the Pathological Anatomy Department, Asturias Central University Hospital for her contribution to the immunofluorescence analysis of the biological samples.

**P. Coto-Segura,<sup>1</sup> M. Fernández-Prada,<sup>2,3</sup>  M. Mir-Bonafé,<sup>1</sup>  B. García-García,<sup>1</sup> I. González-Iglesias,<sup>4</sup> P. Alonso-Penanes,<sup>5</sup> M. González-Guerrero,<sup>6</sup> A. Gutiérrez-Palacios,<sup>6</sup> E. Miranda-Martínez<sup>6</sup> and F. Martín-Torres<sup>3,7,8</sup>**

<sup>1</sup>Dermatology Department, Hospital Alvarez Buylla, Mieres;

<sup>2</sup>Vaccines Unit, Preventive Medicine and Public Health Department, Hospital Alvarez Buylla, Mieres; <sup>3</sup>WHO Collaborating Centre for

Vaccine Safety, Santiago de Compostela, Spain; <sup>4</sup>Emergency Department, Hospital Alvarez Buylla, Mieres; <sup>5</sup>Dermatology

Department, Hospital Universitario de Cabueñes, Gijón, Spain;

<sup>6</sup>Pathological Anatomy Department, Hospital Alvarez Buylla, Mieres,

Spain; <sup>7</sup>Translational Pediatrics and Infectious Diseases, Hospital Clínico Universitario, Universidad de Santiago de Compostela (USC),

Santiago de Compostela, Spain and <sup>8</sup>Genetics, Vaccines and Pediatric Infectious Diseases Research Group (GENVIP), Instituto de

Investigación Sanitaria de Santiago, Universidad de Santiago de Compostela (USC), Santiago de Compostela, Spain

E-mail: mariafdezprada@gmail.com

Conflict of interest: the authors declare that they have no conflicts of interest.

Accepted for publication 6 July 2021

## References

- Martínez-Baz I, Miqueleiz A, Casado I *et al.* Effectiveness of COVID-19 vaccines in preventing SARS-CoV-2 infection

and hospitalisation, Navarre, Spain, January to April 2021. *Euro Surveill* 2021; **26**: 2100438.

- Blumenthal KG, Freeman EE, Saff RR *et al.* Delayed large local reactions to mRNA-1273 vaccine against SARS-CoV-2. *N Engl J Med* 2021; **384**: 1273–7.
- Mockenhaupt M. Bullous drug reactions. *Acta Derm Venereol* 2020; **100**: adv00057.
- Walmsley N, Hampton P. Bullous pemphigoid triggered by swine flu vaccination: case report and review of vaccine triggered pemphigoid. *J Dermatol Case Rep* 2011; **5**: 74–6.
- Stavropoulos PG, Soura E, Antoniou C. Drug-induced pemphigoid: a review of the literature. *J Eur Acad Dermatol Venereol* 2014; **28**: 1133–40.
- Díaz MS, Morita L, Ferrari B *et al.* Linear IgA bullous dermatosis: a series of 17 cases. *Actas Dermosifiliogr (Engl Ed)* 2019; **110**: 673–80.
- Soares CD, Carvalho RA, Carvalho KA *et al.* Letter to Editor: oral lesions in a patient with Covid-19. *Med Oral Patol Oral Cir Bucal* 2020; **25**: e563–4.
- Vojdani A, Kharrazian D. Potential antigenic cross-reactivity between SARS-CoV-2 and human tissue with a possible link to an increase in autoimmune diseases. *Clin Immunol* 2020; **217**: 108480.

## Supporting Information

Additional Supporting Information may be found in the online version of this article:

**Table S1.** Clinical, demographic, vaccine-related variables and histopathological and immunohistochemical characteristics.

**Data S1.** Bibliography.

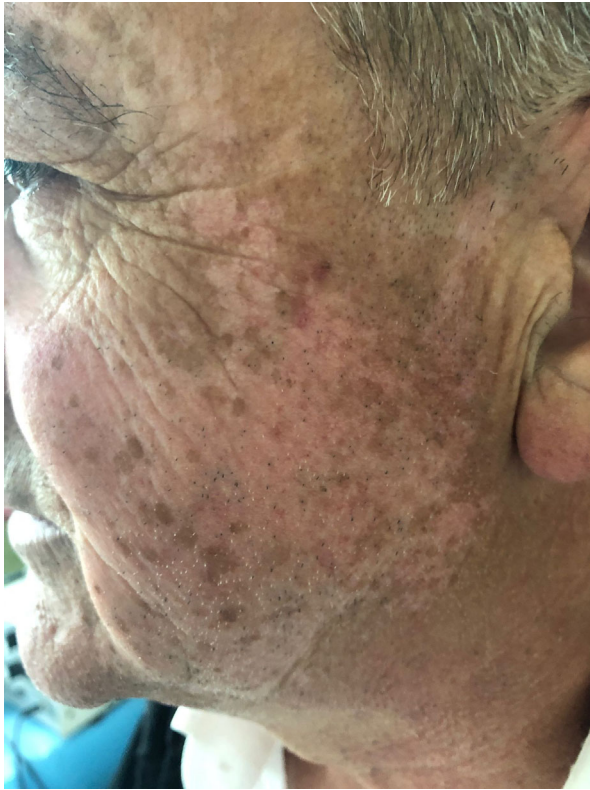## Vitiligo in a COVID-19-vaccinated patient with ulcerative colitis: coincidence?

doi: 10.1111/ced.14842

Dear Editor,

The COVID-19 pandemic has been a global emergency since January 2020. ~~It became clear that it could only be controlled by vaccines; fortunately,~~ several vaccines were developed by the end of 2020. These include mRNA vaccines, which received approval from the US Food and Drug Administration for emergency use.<sup>1</sup> However, as time has passed, a number of adverse events (AEs) have been reported in association with all the vaccines. We report the possible association of vitiligo with the Pfizer-BioNTech vaccine BNT162b2 (Cominarty®) in a patient with ulcerative colitis (UC).

A 58-year-old man presented with white macular plaques distributed symmetrically across his face (Fig. 1), which had appeared 1 week after receiving his first dose of vaccine. The plaques were clinically consistent with



**Figure 1** Diffuse white patches consistent with vitiligo.

vitiligo, and examination under Wood lamp confirmed the initial diagnosis. There were no vitiligo macules seen at any body site other than on his face, even on predilection sites such as the genitalia, axillae and dorsa of the hands, and there was no family history of vitiligo. The patient had a 2-year history of UC for which he was taking azathioprine and sulfasalazine.

The patient was diagnosed with vitiligo, and prescribed tacrolimus ointment twice daily. He attended for follow-up 1 month later, but there was no response seen.

Vaccines stimulate the immune system to produce antibodies. There are studies demonstrating that vaccines can trigger several autoimmune diseases in people with a genetic tendency to those diseases. Several autoimmune diseases, including multiple sclerosis, immune thrombocytopenic purpura and systemic lupus erythematosus have been linked to vaccines such as influenza, hepatitis B and the measles/mumps/rubella vaccines.<sup>2</sup>

Although no cutaneous AEs were encountered in Phase 3 studies of mRNA vaccines, several vaccine-related cutaneous AEs have been reported since the vaccines came into widespread use. These are generally mild and self-limiting, and include local injection-site reactions, delayed large local reactions, urticaria, morbilliform eruptions, erythromelalgia, pemphigoid/chilblains, filler reactions and pityriasis-

rosea-like eruptions.<sup>3</sup> Vitiligo or similar pigmentation-related cutaneous AEs have not been reported to date.

Our patient already had UC, which is an autoimmune disease. Patients with inflammatory bowel disease have been recommended to get a SARS-CoV-2 vaccine even if they are on anti-tumour necrosis factor treatment.<sup>4</sup>

For any treatment method, including vaccines, it is important to assess the risk–benefit balance in the prevention and treatment of disease. Some mild and self-limiting cutaneous AEs are a small risk in relation to the possible fatal outcome of COVID-19 infection. However, vitiligo is a disfiguring skin disorder that may result in stigma and consequent mental distress, particularly if present on visible areas such as the face.

It is not clear if the vitiligo in our patient was caused by vaccination, as patients with pre-existing autoimmune diseases are more likely to also develop other autoimmune diseases.<sup>5</sup> However, the temporal relationship between the vaccine and development of the disease is interesting, and further work is needed to demonstrate a causal relationship between vitiligo and COVID-19 vaccination in patients with autoimmune disorders.

## Acknowledgement

We thank the patient for their written consent for publication of their case and photographs.

**H. Aktas**  and **G. Ertuğrul** 

Department of Dermatology, Karabuk University Faculty of Medicine, Karabuk, Turkey

E-mail: aktashabib@hotmail.com

Conflict of interest: the authors declare that they have no conflicts of interest.

Accepted for publication 7 July 2021

## References

- Polack FP, Thomas SJ, Kitchin N *et al.* Safety and efficacy of the BNT162b2 mRNA covid-19 vaccine. *N Engl J Med* 2020; **383**: 2603–15.
- Vadalà M, Poddighe D, Laurino C, Palmieri B. Vaccination and autoimmune diseases: is prevention of adverse health effects on the horizon? *EPMA J* 2017; **8**: 295–311.
- McMahon DE, Amerson E, Rosenbach M *et al.* Cutaneous reactions reported after Moderna and Pfizer COVID-19 vaccination: a registry-based study of 414 cases. *J Am Acad Dermatol* 2021; **85**: 46–55.
- Alexander JL, Moran GW, Gaya DR *et al.* SARS-CoV-2 vaccination for patients with inflammatory bowel disease: a British Society of Gastroenterology Inflammatory Bowel Disease section and IBD Clinical Research Group position statement. *Lancet Gastroenterol Hepatol* 2021; **6**: 218–24.
- Cojocaru M, Cojocaru IM, Silosi I. Multiple autoimmune syndrome. *Maedica (Bucur)* 2010; **5**: 132–4.